

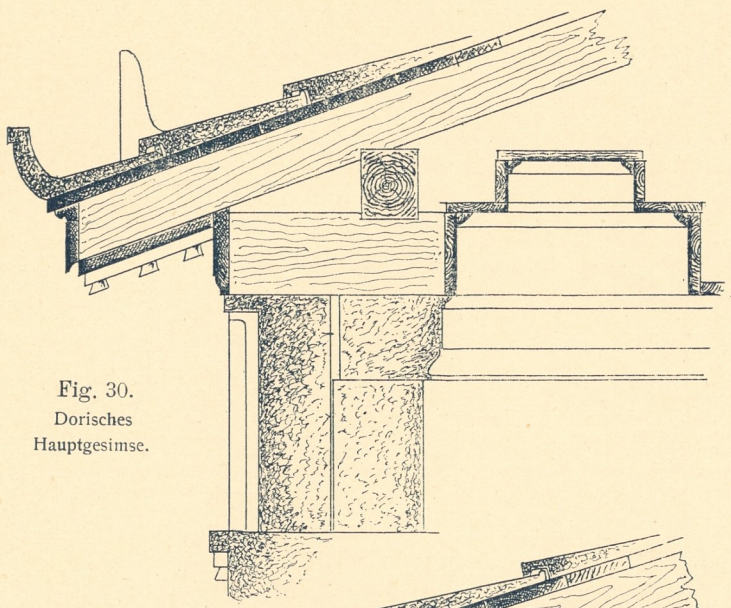Fig. 30.  
Dorisches  
Hauptgesimse.

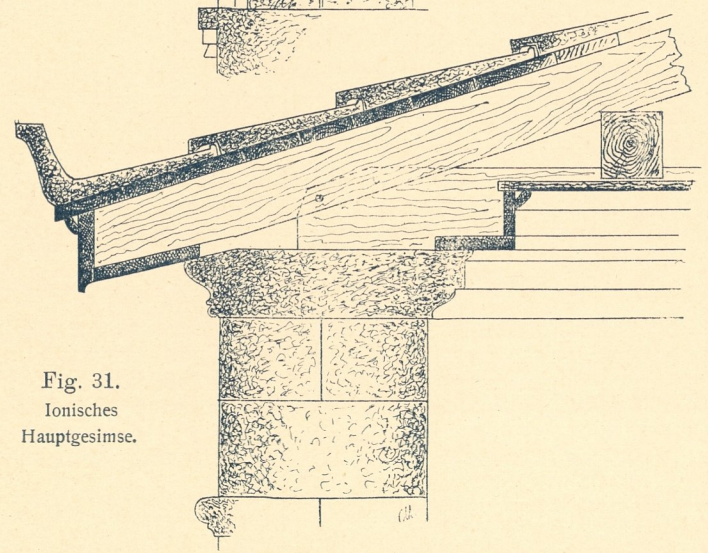


Fig. 31.  
Ionisches  
Hauptgesimse.

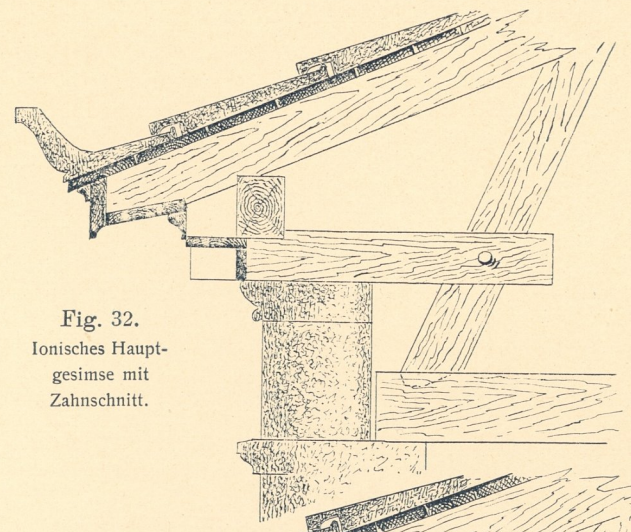


Fig. 32.  
Ionisches Haupt-  
gesimse mit  
Zahnschnitt.

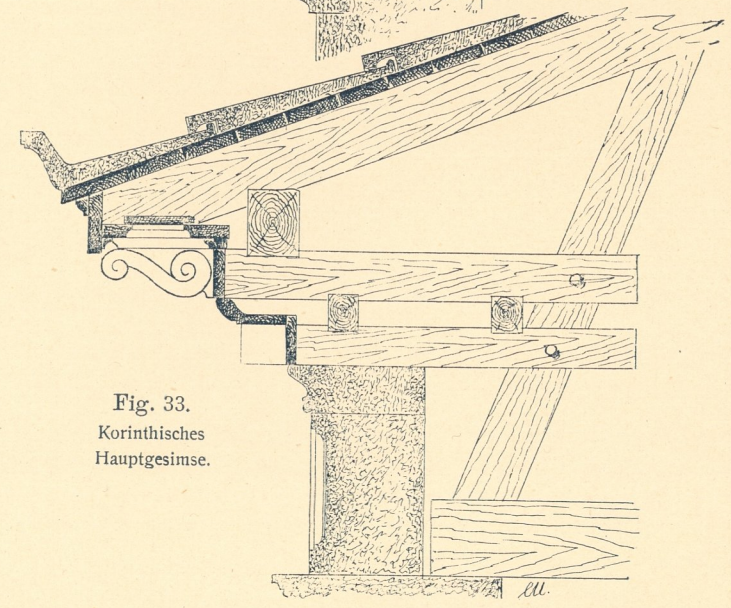


Fig. 33.  
Korinthisches  
Hauptgesimse.