

The Role of Ultrastructural Analysis in the Diagnosis of Tumors: A Single Institution Experience

S. Bulimbasic, A. Racar-Pacic, A. Bauer-Segvic, D. Ljubanovic

Department of Pathology, Dubrava University Hospital,
Av.Gojka Suska 6, Zagreb, HR-10040 CROATIA.

sbulimba@kdb.hr

Keywords: diagnostic pathology, tumors, ultrastructure

Introduction: A few decades ago, electron microscopy played important part of the diagnostic algorithm for variety of tumors, but its importance was downsized due to emergence of other ancillary methods like immunohistochemistry, cytogenetics and methods of molecular analysis which are nowadays widely used in the human medicine. However, ultrastructural analysis could be still valuable technique in certain situations and for selected cases.

Aim: To evaluate contribution of ultrastructural analysis in achieving diagnosis of neoplastic diseases in clinically-oriented environment of Surgical Pathology Department. Furthermore, reasons to request ultrastructural analysis and types of tumors submitted for EM study were analyzed.

Materials and methods: Cases of tumors ultrastructurally analyzed during period 2004-2008 were obtained from the files of the Department of Pathology, Dubrava University Hospital. Samples for light microscopy were routinely processed, embedded in paraffin, cut and stained with hematoxylin and eosin (H&E). Samples submitted for EM analysis were postfixed in osmium tetroxide after cacodylate buffer, embedded in epoxy resins, sectioned and stained with uranyl acetate and lead citrate. Subsequent ultrastructural study was performed on TEM Philips EM400T (during period 2004-2006) and Jeol JEM 1400 (during period 2007-2008). For the purpose of this study, archived microphotographs and digital images of tumor ultrastructure were reviewed, as well as H&E slides of all tumors and immuno stains where available. All photographs and slides were reviewed by two pathologist (S.B. and D.LJ.) and the original diagnoses were confirmed. Results of ultrastructural analysis were divided into four categories: „A“ inadequate material (poorly preserved, necrotic etc.); „B“ preserved but non-diagnostic material, inconclusive; „C“ supportive features; „D“ specific features.

Results: During period 2004-2008 a total of 85 tumors were evaluated by electron microscopy. This cohort includes 10 soft tissue tumors, 35 kidney and 7 other genitourinary (GU) tumors, 9 adrenal gland tumors, 5 hematolymphoid malignancies, 8 pancreatic tumors, 3 breast tumors, and 8 tumors from other organs. Reason to perform ultrastructural analysis was: electron microscopy as a routine part of diagnostic algorithm in 38 cases, confirmation of neuroendocrine differentiation in 16, ambiguous immunohistochemistry results in 11, educational purposes in 12 and scientific interest in the last 8 cases. Results grouped in “A” and “B” category where ultrastructural analysis hasn’t added to the diagnosis comprises 11.8 %, while results in “C” (supportive) and “D” category (specific) comprise 29.4 and 58.8 % of all analyzed cases respectively. The best results were seen in subgroups of kidney tumors (oncocytomas and chromophobe carcinomas; 22/22) and in confirmation of neuroendocrine differentiation (15/16).

Discussion and conclusion: Our study confirms that electron microscopy continues to be useful technique for the diagnosis of selected types of tumors, especially those with

specific ultrastructural features. It may also help to solve real diagnostic difficulties where diagnosis was narrowed but not achieved by use of immunohistochemistry. Furthermore, by use of electron microscopy it's possible to confirm diagnoses of rare entities and provide additional material for further study. Major drawbacks include price, a need for specialized laboratory, sophisticated equipment, educated personnel and pathologists who are familiar with this method and recognize its value. Since both of our GU-pathologists are also involved in evaluation of renal medical diseases (where electron microscopy is irreplaceable method necessary for diagnosis), this could explain disproportionately high number kidney and other GU tumors included in this study.

1. I. Dardick et al., Hum pathol **29** (1998) p12335-8.
2. B. Krishnan et al., Hum Pathol **33** (2002) p68-79.
3. M.M. Picken, Ultrastruct Pathol **29** (2005) p277-82.

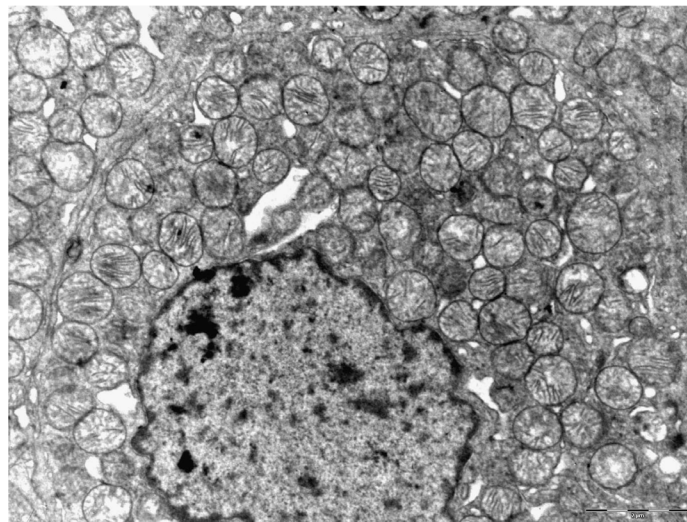


Figure 1. Renal oncocytoma: cytoplasm filled with mitochondria (uranil acetate-lead citrate, original magnification 10 000 x)

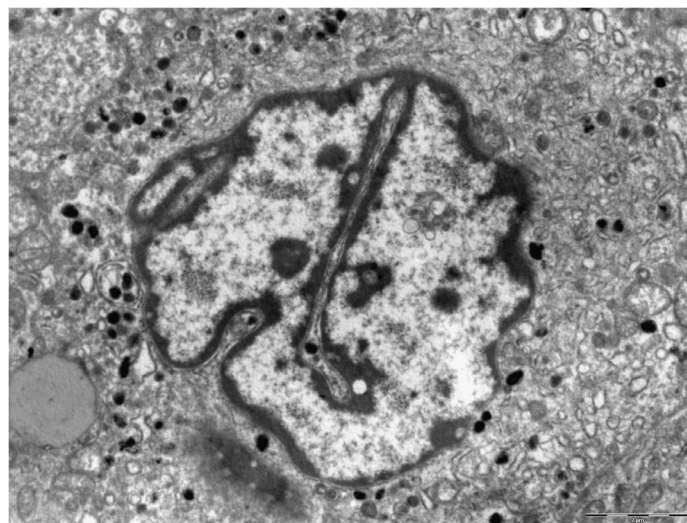


Figure 2. Cytoplasmic premelanosomes in the amelanotic metastatic melanoma (uranil acetate-lead citrate, original magnification 6 000 x)